

Original contributions

A systematic algorithm for the management of lower lip asymmetry[☆]

Robin W. Lindsay, MD^{a,b,*}, Colin Edwards, BA^a, Chris Smitson, BS^a,
Mack L. Cheney, MD^a, Tessa A. Hadlock, MD^a

^aDepartment of Otolaryngology/Head and Neck Surgery, Massachusetts Eye and Ear Infirmary and Harvard Medical School, Boston, MA, USA

^bDepartment of Surgery Uniformed Services University of the Health Sciences, Bethesda, MD, USA

Received 20 May 2009

Abstract

Purpose: An asymmetric smile, caused by loss of function of the lip depressors, can be functionally and cosmetically debilitating. Although some surgeons report excellent results with muscle transfer to the lower lip, many facial reanimation surgeons find that dynamic techniques do not consistently address the lower lip. Our objectives were to retrospectively review our outcomes after treatment of the asymmetric lower lip, and to propose a progressive, stepwise algorithm for the management of lower lip asymmetry in facial paralysis.

Material/Methods: Retrospective chart review was performed on all patients treated in a multidisciplinary facial nerve center with lower lip asymmetry over an eighteen month period. Treatment ranged from a temporary trial of lidocaine, to chemodenervation with botulinum toxin, to pedicled digastric muscle transfer, and/or resection of the nonparetic depressor labii inferioris (DLI).

Results: Fifty-seven patients were treated with chemodenervation with botulinum toxin, four with anterior belly of the digastric transfer, and 3 with DLI resection. All patients with DLI resection had undergone chemodenervation to the contralateral lower lip with botulinum toxin and were pleased with the appearance of their smile.

Conclusions: We have found that lower lip asymmetry is optimally managed by adherence to a standardized protocol that offers patients insight into the likely outcome of chemodenervation or surgery and progresses systematically from the reversible to the irreversible. We present our algorithm for the management of the asymmetric lower lip, which reflects this graduated approach and has resulted in high patient satisfaction.

Published by Elsevier Inc.

1. Introduction

Facial paralysis can create severe debilitation and social isolation. The inability to depress the lower lip, from either an isolated marginal mandibular nerve paralysis or a complete facial paralysis, significantly limits a patient's ability to express a range of emotions. Patients with lower lip asymmetry are not able to depress, lateralize, or evert the

lower lip, resulting in a smile pattern characterized by an elevated and inverted lower lip. Smile asymmetry is especially pronounced in patients with a "full denture" smile, in which all muscles are activated when smiling [1].

Techniques to manage the asymmetric lower lip revolve around either restoration of dynamic depressor muscle function on the paralyzed side [2-6] or the weakening of functional side to improve symmetry [7-11]. Methods that restore dynamic depressor muscle function have been reported in the literature, but require moderately involved surgical procedures under general anesthesia, and yield unpredictable results. Techniques that weaken the functional side, by chemodenervation with botulinum toxin or by depressor labii inferioris (DLI) resection, have been shown to be safe and effective office-based procedures, yielding

[☆] Presented at the XI International Facial Nerve Symposium, Rome, Italy April 25–28, 2009.

* Corresponding author. Department of Otolaryngology Head and Neck Surgery, National Naval Medical Center, 8901 Wisconsin Ave, Bethesda, MD 20889, USA. Tel.: +1 617 573 3641; fax: +1 617 573 3727.

E-mail address: robin.lindsay@meei.harvard.edu (R.W. Lindsay).

high patient satisfaction [8,10,11]. Despite this, patients with unilateral facial weakness are frequently psychologically unprepared for the suggestion that removal of additional facial movement might provide a benefit.

Many centers manage patients with lower lip asymmetry; however, in the current literature, a systematic management strategy, using a multitude of available techniques, does not exist. Herein, we describe our management of patients with lower lip asymmetry, and suggest an algorithm for the stepwise management of the asymmetric lower lip that we have found provides improved balance of the lower lip during facial expression, and higher patient satisfaction.

2. Anatomy

The depressor muscles of the lower lip include the DLI, the depressor anguli oris (DAO), and the platysma muscle [1,10,11]. The mentalis muscle, located medial to this complex of muscles, acts as a lower lip elevator and everter. The DLI is the muscle most responsible for depression of the lower lip. It originates from the lower lateral surface of the body of the mandible, inferior to the mental foramen and inserts into the inferior and superficial surface of the orbicularis oris. At its origin, the DLI is 3 cm wide and covered laterally by the DAO for 1 to 2 cm, narrowing to 2 cm before insertion. The DLI everts the vermilion and depresses and lateralizes the lower lip. The DAO originates from the mandible, superficial to the DLI, and inserts onto the modiolus to depress the corner of the mouth. The platysma muscle plays a minor role in depressing the lip through its facial connections, although its resting tone can influence the resting, static position of the lower lip [1].

3. Patients and methods

A retrospective chart review was performed on all patients evaluated and treated in a multidisciplinary facial nerve center setting over an 18-month period who demonstrated lower lip asymmetry as a result of facial paralysis. Our stepwise clinical approach has evolved over the previous four years, and now begins with a one-time lidocaine injection to provide an immediate but short-lived visual sense of the potential effect of chemodenervation. If balance is improved and oral competence maintained, chemodenervation with botulinum toxin is offered. During the study period, DLI division was offered in cases where repeat injections with botulinum toxin met with high satisfaction, and digastric transfer was offered in patients who categorically declined any “weakening” interventions or who were unhappy with the results of lower lip weakening. This study was approved by the institutional review board at the Massachusetts Eye and Ear Infirmary.

3.1. Technique for local anesthetic injection

The depressor labii inferioris muscle was identified by palpation of the lower lip, near the junction of the medial and lateral lower lip, while the patient was asked to fully animate his or her lip complex (Fig. 1). The area of maximal resistance, noted as the examiner pushed up on the vermilion border, corresponded with the location of insertion of the DLI. The point of injection of local anesthesia was into the midsection of the muscle along its lateral border, to prevent inadvertent injection into the orbicularis oris muscle [10]. The injections were performed in the office setting, with 2 mL of 1% lidocaine containing 1:100 000 epinephrine.

3.2. Technique for chemodenervation with botulinum toxin

If a patient was satisfied with the results of the motor blockade by injection with lidocaine, the patient was offered chemodenervation with botulinum toxin at the next clinic visit. The DLI muscle was identified in the same fashion as described for local anesthetic injection [10]. Five units of botulinum toxin type A (100 U was mixed with 2 mL of normal saline creating a 5 U/.1 mL solution) was then injected into the midsection of the depressor labii inferioris muscle. Patients were seen in follow-up 2 to 3 weeks post injection to determine the success of the treatment. If the patient was satisfied with the results from chemodenervation, repeat injection was offered at 4- to 6-month intervals.

3.3. Technique for depressor labii inferioris division

Patients that continued to be satisfied with the results of chemodenervation after serial chemodenervation treatments were offered DLI resection (Fig. 2). Ordinarily, DLI resection was performed in the clinic under local anesthesia.

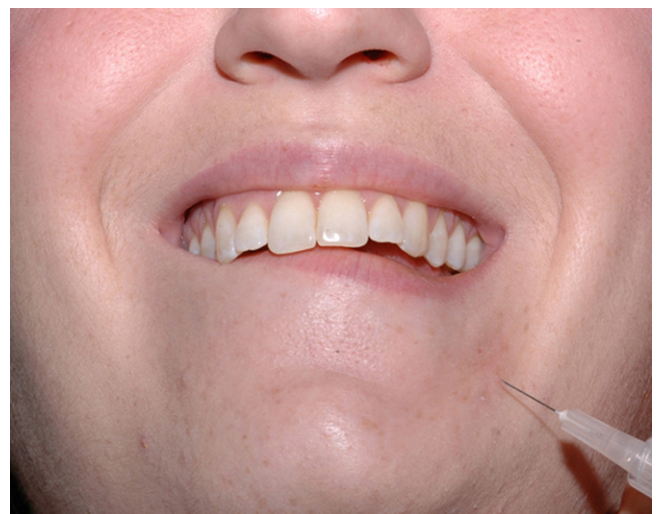

Fig. 1. Demonstration of the injection site used to deliver lidocaine into the midpoint of the depressor labii inferioris (DLI) muscle.

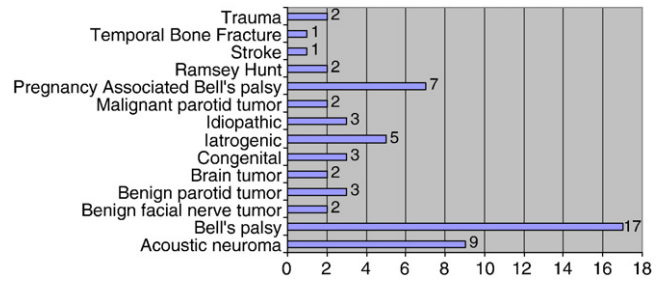
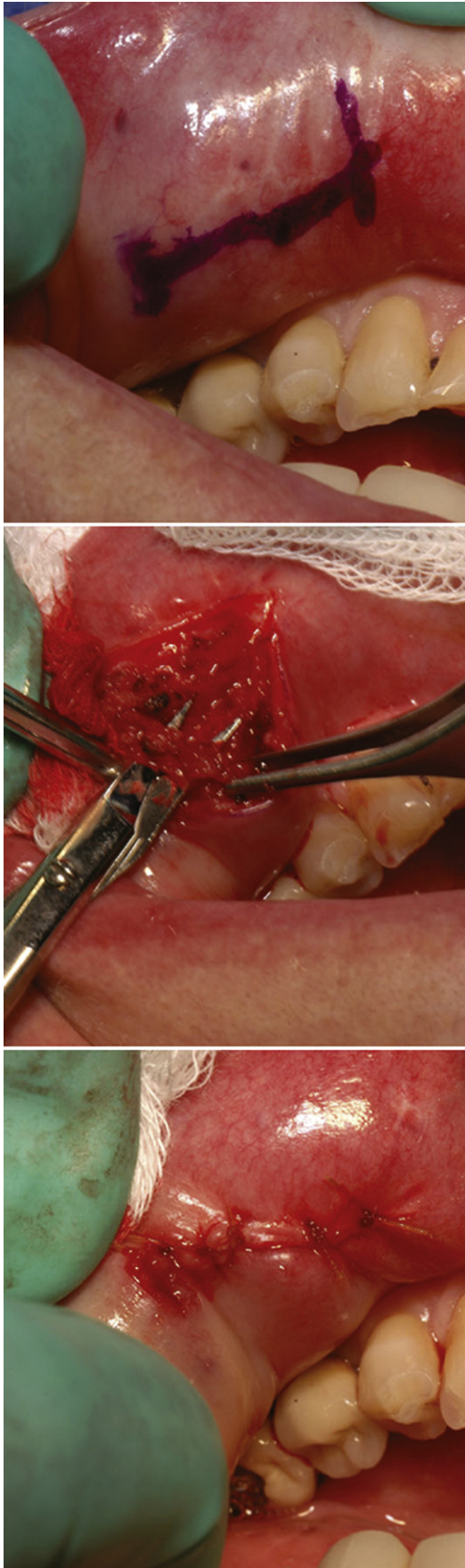


Fig. 3. Chart reflecting the various etiologies of facial paralysis in patients undergoing treatment of an asymmetric lower lip.

The lower lip was anesthetized with 1% lidocaine with 1:100 000 epinephrine. An incision was made in the mucosa of the right lower lip, approximately 1 cm below the margin of the lip. The fibers of the DLI were identified, and a 1 cm length of muscle was excised. The incision was closed in layers.

3.4. Technique for anterior belly of digastric transfer

Under general anesthesia, an incision 2 cm inferior to the inferior mandibular margin was made. The anterior belly of the digastric and the digastric tendon were mobilized to the anterior border of the mandible. Care was taken to preserve the neurovascular pedicle entering the muscle its deep, lateral surface. Care was taken to harvest the digastric tendon in its entirety to ensure adequate length of the transposed tissue. The digastric tendon was cut longitudinally into several slits, and tunneled to the lower lip vermillion border. A 2-cm incision along the white roll was performed and the tendon was sutured to the orbicularis oris musculature, followed by closure of the incisions [6].

4. Results

Fifty-eight patients were treated for lower lip asymmetry at the MEEI Facial Nerve Center, over an approximately 18-month period. The average patient age was 48 years (range, 14–84 years; SD, 14). The average follow-up period was 18.3 months (range, 10–30; SD, 5.9). Fig. 3 summarizes the etiologies of the facial nerve paralysis. Ten patients had isolated marginal mandibular branch or segmental dysfunction, 44 had incomplete unilateral facial paresis, and 4 had unilateral complete facial paralysis.

Fifty-seven patients were treated with chemodenervation with botulinum toxin, 4 with anterior belly of the digastric transfer, and three with DLI resection. Injection of 2 mL of 1% lidocaine reflected the functional and aesthetic results that a patient could expect with botox (Fig. 4). One patient with DLI resection required repeat resection; however, all

Fig. 2. Division of the DLI muscle. Incision site (upper). DLI muscle identification and division (middle). Incision closure (lower).

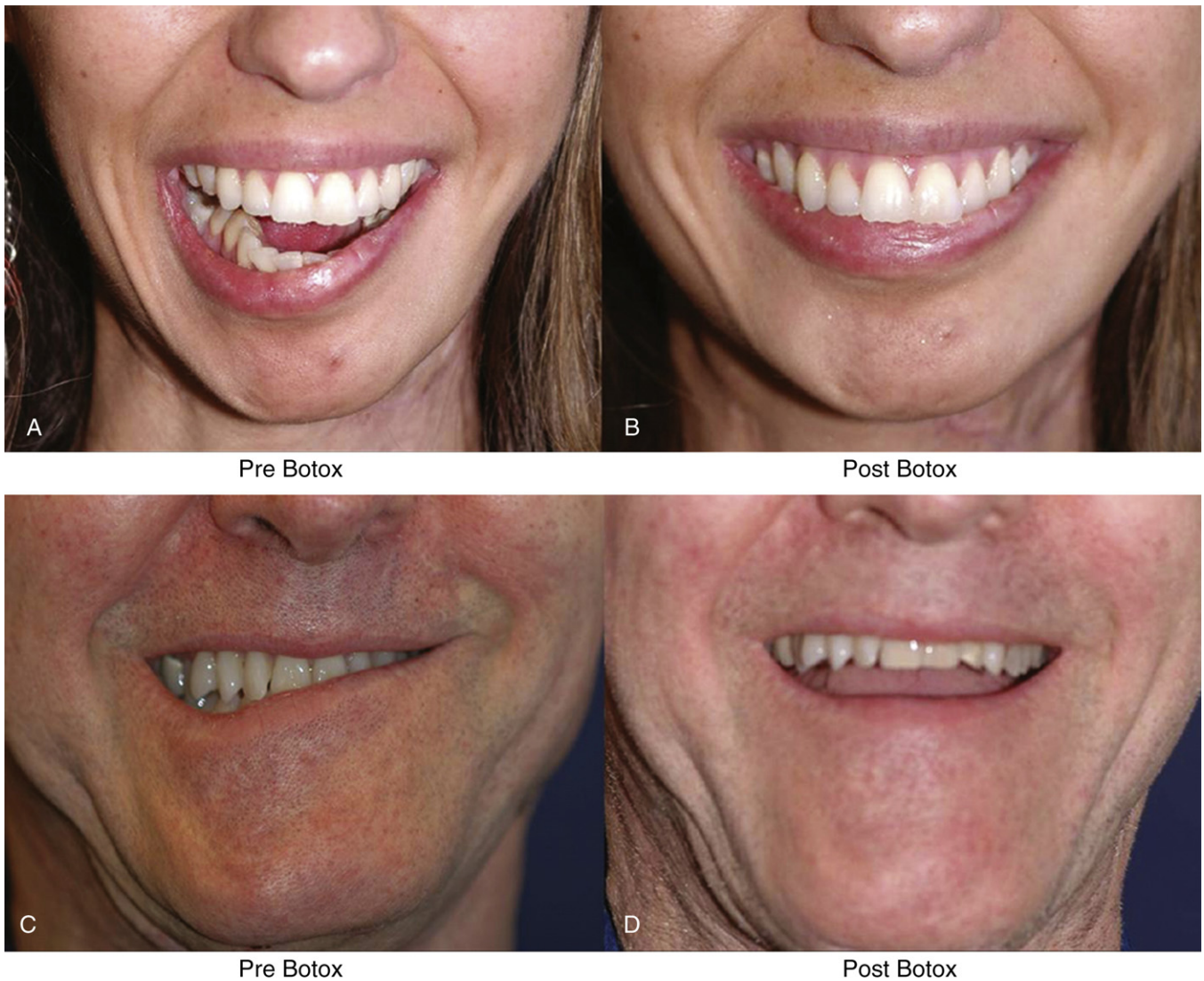

Fig. 4. Chemodenervation with botulinum toxin. (A and B) Note the asymmetry of the lower lip prior to chemodenervation. (C and D) Observe the improved symmetry of the lower lip after chemodenervation.

were satisfied with the final result (Fig. 5). None of the patients treated with chemodenervation or DLI resection reported infection, poor aesthetic result, interference with speech, mental nerve injury, or oral incompetence.

Of the 57 patients treated with chemodenervation, 48 patients were happy with the results and received 2 or more treatments (84.2% success rate). Three of the patients who were not satisfied with the results of contralateral lower lip chemodenervation elected to have anterior belly of digastric transfer for lower lip reanimation. The other 6 patients dissatisfied with chemodenervation elected not to undergo further treatment.

Patients treated with anterior belly of digastric transfer had inconsistent results. Three of 4 were satisfied with their results (Fig. 6); however, 1 patient required reversal of the procedure for management of excessive bulk at the vermillion border.

5. Comment

The management of patients with facial paralysis has undergone many changes over the past thirty years. Microsurgical techniques and a deeper appreciation of neuromuscular physiology have lead to a wider variety of techniques to manage the asymmetric lower lip, amongst these instruments are free extensor digitorum brevis transfer, anterior belly of the digastric transfer, minihypoglossal nerve transfer to the cervicofacial branch, direct neurotization of the depressor muscle, and platysma muscle transfer [2,5,6,12]. Invasive management strategies for the contralateral side include neurectomy of the contralateral marginal mandibular branch [7]. All of the above procedures require general anesthesia and advanced surgical techniques with inconsistent and sometime unsatisfactory lower lip symmetry and function.

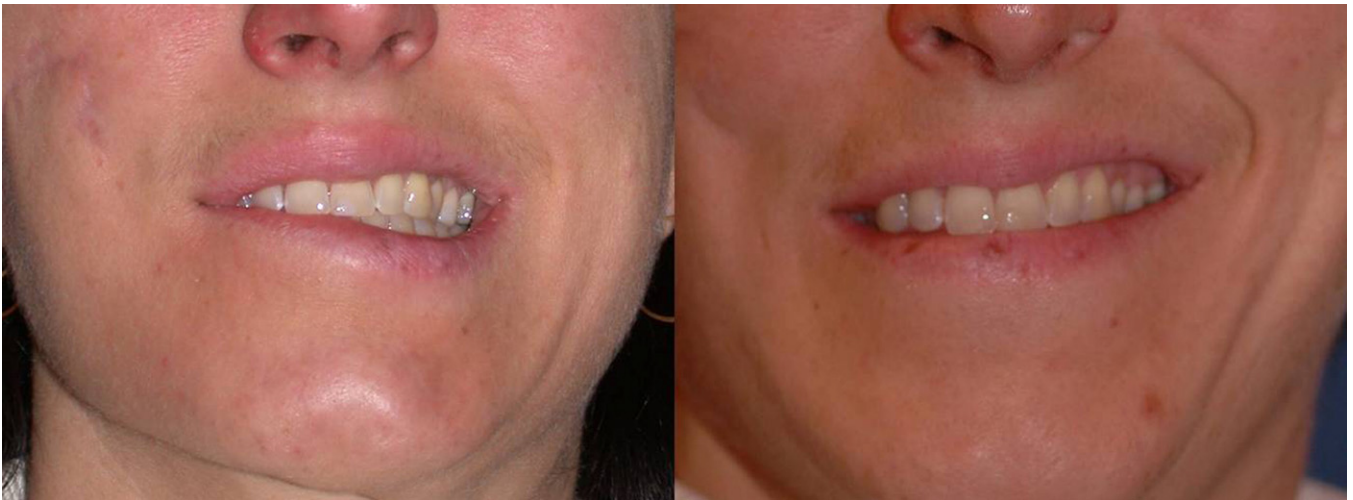

Fig. 5. DLI division. (Left) Patient with a traumatic facial nerve injury showing asymmetry of the lower lip. (Right) Improved symmetry of the lower lip after resection of the DLI muscle.

Office-based procedures for the management of the asymmetric lower lip provide safe and reliable results, without the need for general anesthesia. For 20 years, botulinum toxin has been used to treat the contralateral side in patients with facial nerve paralysis [9]. More recently, chemodeneration with botulinum toxin has been shown to produce a balanced smile without oral incompetence or interference with speech [8]. Depressor labii inferior resection has been shown to produce a more symmetric smile and decrease the amount patients bite their lower lip, without causing oral incompetence or speech problems [11]. In addition, patients preferred bilateral lack of movement of the lower lip over the lack of symmetry when expressing emotion [11]. To help to determine patient satisfaction before DLI resection, Manktelow et al [10] showed that a trial of local anesthetic before DLI resection provided

patients with valuable insight into the likely outcome of the surgery.

Given the success of office-based procedures of the lower lip, we have developed a treatment algorithm to integrate existing management techniques to improve patient satisfaction and ultimate preparedness for contralateral lower lip weakening (Fig. 7). Like Manktelow, we propose that all patients considering contralateral weakening first receive a trial injection of lidocaine. If a patient is pleased with the results of the short acting muscle blockade, we recommend chemodeneration with botulinum toxin. If, after three serial chemodeneration treatments spaced 4 to 6 months apart, a patient continues to receive significant benefit, we then recommend DLI resection. This permits a prolonged decision-making period, during which a patient can see and understand the effect of contralateral lower lip

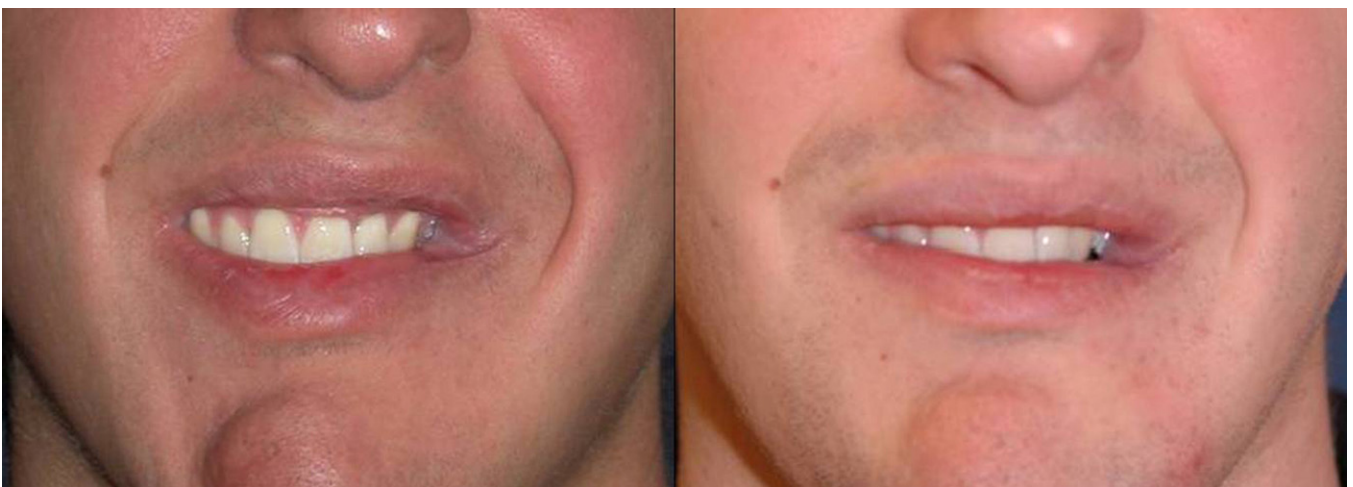

Fig. 6. Anterior belly of the digastric transfer. (Left) Asymmetric lower lip prior to treatment. (Right) Improved symmetry of the lower lip after muscle transfer.

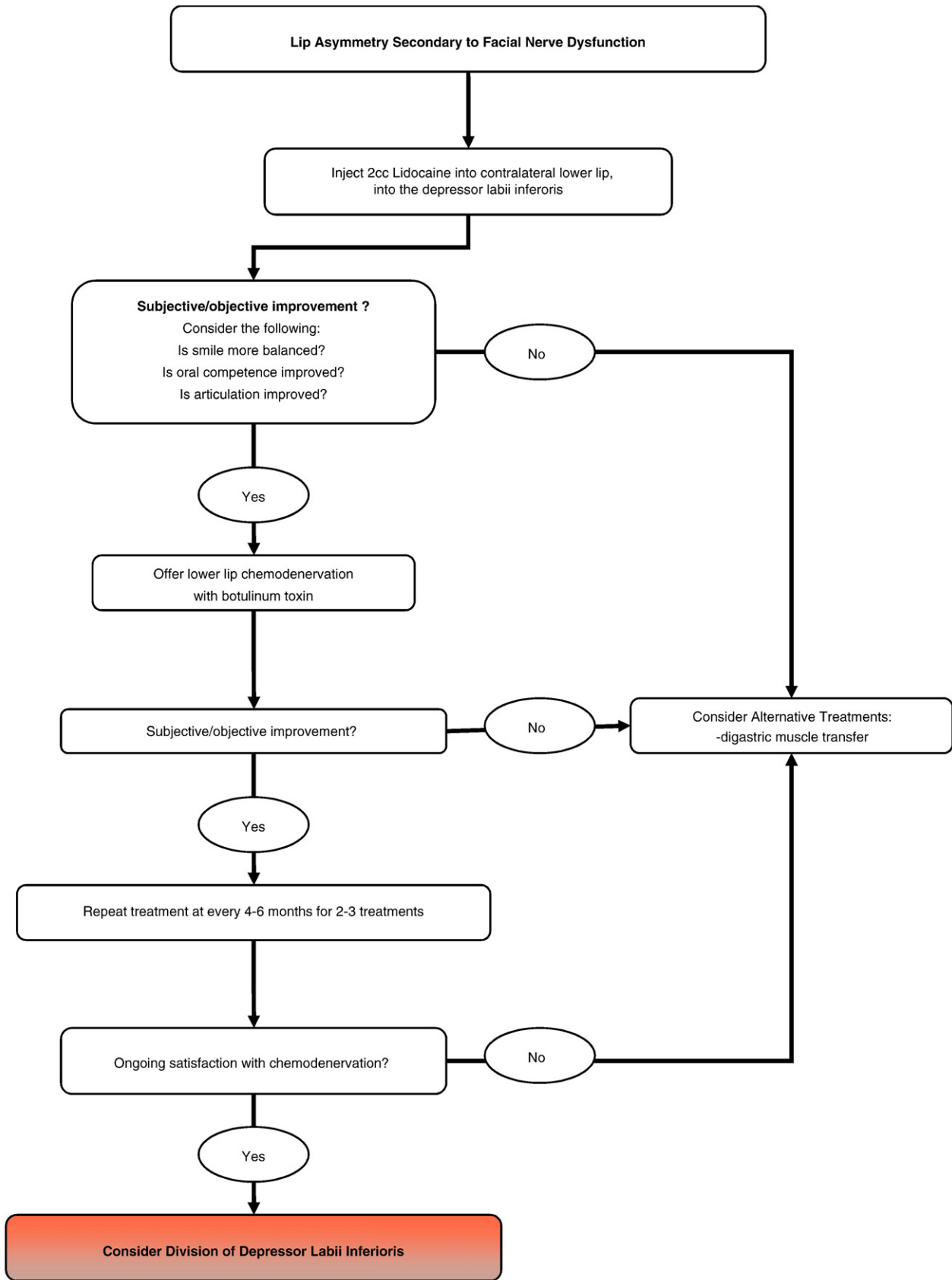


Fig. 7. Treatment algorithm to integrate existing management techniques to improve patient satisfaction and ultimate preparedness for contralateral lower lip weakening. Note the use of repeated botox injections prior to performing DLI resection.

weakening. Frequently, the effect has to be present for a significant period (months) and then allowed to wear off before it can be fully appreciated. Patients who underwent DLI resection preferred this procedure over recurrent chemodenervation because it produced a symmetric smile without the need for repeated treatments.

Patients with facial paralysis have significant distress about their decreased ability to express emotion in a social setting. Whether a patient has isolated congenital unilateral lower lip paresis or complete facial paralysis, accepting the notion of weakening the functional side is often an emotionally trying decision. Our algorithm provides an organized treatment strategy, which permits patients to be treated with proven interventions and to decide if they are likely to benefit from surgery before undergoing definitive DLI resection. Surprisingly, we have additionally found that favorable results from free gracilis transfer for smile reanimation called new attention to the lower lip area. Patients, whose initial dominant complaint was lack of smile, began to complain newly of lower lip asymmetry, after successful smile reanimation. Therefore, the algorithm is also suitable for patients in which lower lip asymmetry was not initially a dominant complaint, but who experience lower lip asymmetry after successful smile reanimation.

6. Conclusions

The management of facial nerve disorders remains a complex entity without widely excepted pathways for the management of many facial zones. Management of lower lip asymmetry can make critical differences in facial balance and should no longer be overlooked. We suggest that adherence to the management elements presented within this algorithm for lower lip asymmetry will improve outcomes, largely by permitting patients to appreciate for themselves whether decreasing the function of the contralateral lower lip provides a significant benefit in their individual clinical situation.

Acknowledgments

Dr Robin Lindsay and Dr Tessa Hadlock had full access to all of the data in the study and take responsibility for the integrity of the data and the accuracy of the data analysis.

References

- [1] Rubin LR. The anatomy of a smile: its importance in the treatment of facial paralysis. *Plast Reconstr Surg* 1974;53:384-7.
- [2] Conley J, Baker DC, Selfe RW. Paralysis of the mandibular branch of the facial nerve. *Plast Reconstr Surg* 1982;70:569-77.
- [3] Spector GJ, Matsuba HM, Killeen TE, et al. Fascial pulley: cross-commissure lip reanimation for inferior division facial nerve paralysis. *Laryngoscope* 1986;96:102-5.
- [4] Spira M. Anastomosis of masseteric nerve to lower division of facial nerve for correction of lower facial paralysis. *Plast Reconstr Surg* 1978;64:330-4.
- [5] Tan ST. Anterior belly of digastric muscle transfer: a useful technique in head and neck surgery. *Head Neck* 2002;24:947-54.
- [6] Terzis JK, Kalantarian B. Microsurgical strategies in 74 patients for restoration of dynamic depressor muscle mechanism: a neglected target in facial reanimation. *Plast Reconstr Surg* 2000;105:1917-31 [discussion 1932-1914].
- [7] Breslow GD, Cabiling D, Kanchwala S, et al. Selective marginal mandibular neurectomy for treatment of the marginal mandibular lip deformity in patients with chronic unilateral facial palsies. *Plast Reconstr Surg* 2005;116:1223-32.
- [8] Chen CK, Tang YB. Myectomy and botulinum toxin for paralysis of the marginal mandibular branch of the facial nerve: a series of 76 cases. *Plast Reconstr Surg* 2007;120:1859-64.
- [9] Clark RP, Berris CE. Botulinum toxin: a treatment for facial asymmetry caused by facial nerve paralysis. *Plast Reconstr Surg* 1989;84:353-5.
- [10] Godwin Y, Tomat L, Manktelow R. The use of local anesthetic motor block to demonstrate the potential outcome of depressor labii inferioris resection in patients with facial paralysis. *Plast Reconstr Surg* 2005;116:957-61.
- [11] Hussain G, Manktelow RT, Tomat LR. Depressor labii inferioris resection: an effective treatment for marginal mandibular nerve paralysis. *Br J Plast Surg* 2004;57:502-10.
- [12] Tulley P, Webb A, Chana JS, et al. Paralysis of the marginal mandibular branch of the facial nerve: treatment options. *Br J Plast Surg* 2000;53:378-85.