

The value of spreader grafts in rhinoplasty: a critical review

A. Teymoortash · J. A. Fasunla · A. A. Sazgar

Received: 29 April 2011 / Accepted: 1 November 2011
© The Author(s) 2011. This article is published with open access at Springerlink.com

Abstract The value of spreader grafts in rhinoplasty cannot be underestimated. Various studies have demonstrated that they play a valuable role in the restoration of nasal dorsum aesthetics, provide support for the nasal valve and maintain the straightened position of the corrected deviated cartilaginous septal dorsum. However, there is still controversy on the extent of its value in nasal patency. This study reviews the literature and describes the values and limitations of spreader grafts in rhinoplasty and the alternatives to classic spreader grafts.

Keywords Rhinoplasty · Spreader grafts · Nasal valve collapse · Crooked nose · Humpy nose

Introduction

Nasal valve collapse is related to deficiencies in the structural support of the lateral nasal wall. Facial plastic surgeons and rhinologists should be aware not to overzealously remove nasal tissues and ensure that the nasal valve angle is not compromised during the surgical procedure. This can significantly complicate functional and aesthetic results after rhinoplasty [1]. In the 1980s, Sheen [2] popularized spreader grafts as a method of reconstruct-

ing the internal nasal valve and recontouring the aesthetic appearance of the nasal dorsum in rhinoplasty. Since that time, spreader grafts are commonly indicated in cases of primary and secondary rhinoplasty. Conceptually, the grafts were used to act as volumetric expanders to stabilize and shift the upper lateral cartilage away from the dorsal septum to increase the internal nasal valve angle. This article reviewed the literature and reported on the values of spreader grafts in rhinoplasty.

Etiology, diagnosis, and treatment of the nasal valve collapse

The internal nasal valve is the narrowest part of the nasal airway and its cross-sectional area is determined by the angle formed between the caudal part of the upper lateral cartilage and nasal septal cartilage [3, 4]. The average angle of the nasal valve in a normal Caucasian ranged from 9 to 15° [4, 5]. The anterior end of the inferior turbinate and the tissues surrounding the pyriform aperture may affect this cross-sectional area. Nasal valve collapse occurs when this narrowest part becomes weak and narrower than 9° [3]. This angle, however, varies between Caucasians, African-Americans, and Asians. Whenever patients breathe in, airflow through the internal nasal valve increases and the intra-luminal pressure decreases according to Bernoulli's principle. This drop in intra-luminal pressure interferes with the normal flow of air in the nasal cavity and sucks the nasal cartilaginous side wall in. This results in nasal obstruction, which is experienced by these patients.

Nasal valve collapse is a common anatomical cause for nasal obstruction [1, 2]. The etiology may be congenital, traumatic, or iatrogenic, especially after septorhinoplasty [1, 2, 5]. Factors like septal deviation, aging, facial nerve

A. Teymoortash (✉) · J. A. Fasunla
Department of Otolaryngology, Head and Neck Surgery,
Philipp University, Baldinger Str., 35043 Marburg, Germany
e-mail: teymoort@med.uni-marburg.de

A. A. Sazgar
Department of Otolaryngology, Head and Neck Surgery,
Vali-Asr Hospital, Tehran University of Medical Sciences,
Tehran, Iran

paralysis or paresis, allergic and non-allergic rhinitis may contribute and worsen nasal valve insufficiency [6, 7].

The middle third of the nose consists of the paired upper lateral cartilages, the dorsal part of the septum, and the scroll of the upper lateral cartilages upon the lower lateral cartilages. This area plays an important role in the nasal valve function. Anatomical distortion of this area during rhinoplasty by cephalic resection of the lateral crura of the alar cartilages, as well as lateral osteotomies, can weaken the physiological support of the upper lateral cartilages; this results in the medialization of these tissues. In addition, removal of the nasal hump during rhinoplasty may distort the junction of the upper lateral cartilages and the septum, causing collapse of the internal nasal valve angle.

Many rhinologists use Cottle's maneuver for the diagnosis of nasal valve collapse, when nasal obstruction is relieved by just lifting the soft tissues of the ipsilateral cheek or naso-labial fold [8]. However, this sign is not specific for internal nasal valve collapse as the improvement in nasal breathing can also be experienced in patients with other causes of nasal obstruction. Subjective impression of patient's nasal breathing and anterior rhinoscopy during quiet and forced inspiration with endonasal palpation and lateralization of collapsed parts of the nasal valve can better indicate nasal valve insufficiency. Modified Cottle's maneuver was developed to identify the degree and location of specific anatomic abnormalities in the nose [9]. It was designed to use an ear curette during nasal manipulations for lifting the lower and upper lateral cartilages separately, while the patients rate their breathing. Constantinides et al. [9] found the method to be useful as a reliable aid in preoperative evaluation of nasal obstruction and postoperative assessment of nasal patency.

Rhinomanometry is an objective test used to assess nasal obstruction [2, 10]. It measures both the intranasal air pressure and the rate of airflow during breathing. However, lateralization of the nasal wall due to the nasal adaptor of rhinomanometric equipment diminishes its reliability in the assessment of nasal valve collapse. This may cause alteration in the cross-sectional area of the internal nasal valve with wrong results.

Nasal valve dilator devices can improve nasal obstruction caused by nasal valve collapse. However, most patients abandon using this device after a short while since it is usually uncomfortable and may cause skin irritation. In view of the fact that nasal valve collapse is an anatomical problem, surgical treatment is a better and definitive option for its correction. There are a number of surgical approaches available to treat nasal valve collapse. These approaches may involve the use of butterfly grafts, alar batten grafts, suspension sutures, flaring sutures, and spreader grafts in rhinoplasty [5–8, 11–13]. Selection of the appropriate surgical intervention depends on proper identification of the

anatomic cause of the collapse. Spreader grafts play a role in the treatment of nasal valve collapse by widening the nasal valve angle and maintaining the widened angle with variable degrees of success [5, 7, 11, 14]. This limitation of spreader grafts will be discussed later.

Humpy nose

A humpy nose is among the main reasons for rhinoplasty. It can be inherited or posttraumatic and the skeletal framework of the hump may contain cartilaginous or bony components. Removal of the hump usually leaves a flat and open roof, causing weakness of tissues at the junction of septal dorsum and upper lateral cartilage, and compromises the nasal valve angle. Following the reduction of the nasal hump to a desired level, spreader grafts are usually positioned to prevent the complication of nasal valve collapse. The placement of two parallel cartilaginous spreader grafts alongside the nasal dorsum has been reported to prevent this problem [2] (Fig. 1). In addition, they restore the dorsal aesthetic eyebrow-nasal lines of the nasal dorsum [15].

Crooked nose

A crooked nose may be congenital or acquired. The acquired crooked nose is more common and typically caused by trauma [16]. These deformities are usually due to a set of anatomical abnormalities and result in aesthetic and functional problems. The associated anatomical abnormalities include septal cartilage and vomer deviation, or their misalignment on the maxillary bone and deformity of nasal bone and tip [17]. During septorhinoplasty to reconstruct the deviated nose, both lateral and medial nasal osteotomies are carried out so that the deviated nose can be disconnected from its bony attachments for easy repositioning at the midline. Spreader grafts are then inserted between the upper lateral cartilages and the upper part of septal cartilage for structural reinforcement and straightening of the cartilaginous crooked nose [18] (Fig. 2). Unilateral spreader grafts or spreader grafts with different thicknesses may be used in these patients, and the grafts help to maintain the nasal pyramid in a straight position at the midline.

Reconstruction of the nasal dorsum

Septal integrity depends on a strong L-shaped dorsal and caudal cartilaginous strut with attachments to the nasal bones and maxilla. Loss of the septal height and tip support causes saddle deformity of the lower two-thirds of the nasal dorsum. A saddle nose results from a wide range of conditions like

Fig. 1 Spreader grafts in an open approach rhinoplasty to correct a humpy nose. **a** Septal cartilage, nasal bone, and the bilateral upper lateral cartilages were exposed after hump removal, **b** Spreader grafts were positioned between the upper part of septum and upper lateral cartilages after lateral and medial osteotomy, **c** Spreader grafts from posterior part of the septum

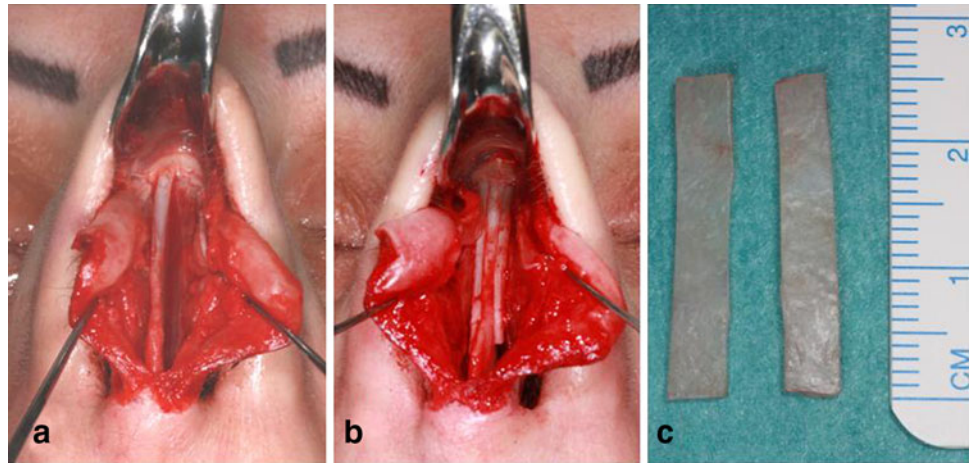
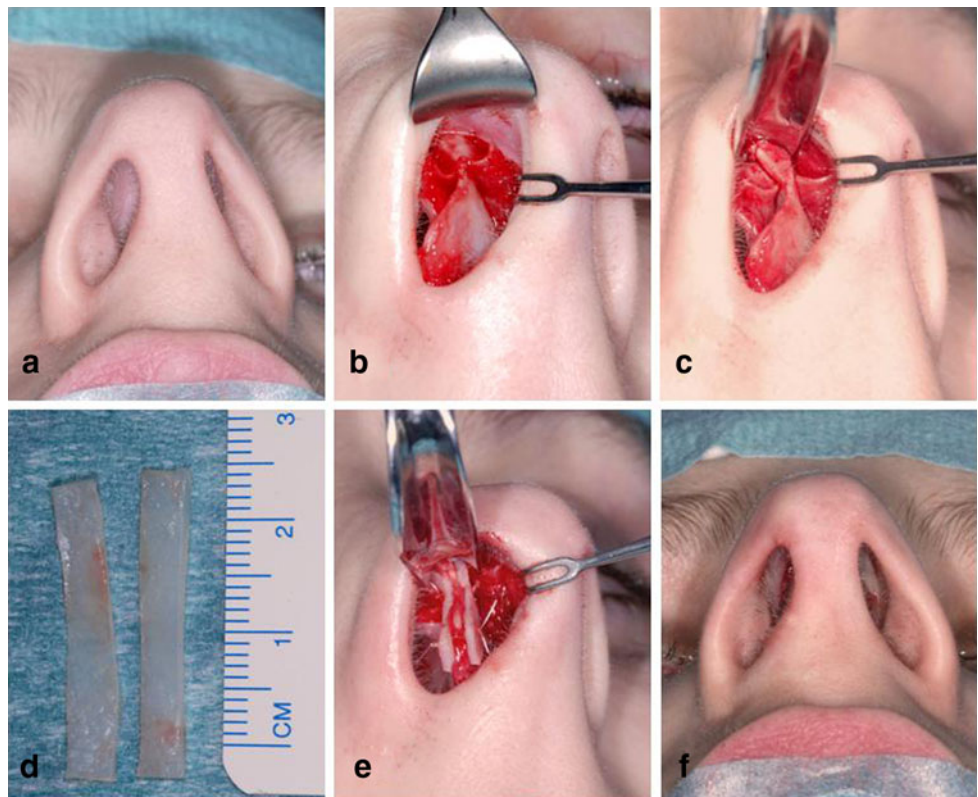


Fig. 2 Serial stages in a closed approach rhinoplasty to correct a deviated nose with spreader grafts. **a** Preoperative cartilaginous deviated nose to the right side, **b** Exposure of septal cartilage and upper lateral cartilages via closed rhinoplasty, **c** Upper lateral cartilages are separated from the septal cartilage, **d** Spreader grafts from posterior part of the septum, **e** Harvested spreader grafts are positioned between the upper lateral cartilage and the upper part of septal cartilage on both sides, **f** Intraoperative view of the straight nasal axis after insertion of the spreader grafts



septal perforation, facial trauma, septo(rhino)plasty, cocaine abuse and systemic diseases like Wegener’s granulomatosis and T-cell lymphoma [19, 20].

While minimal deformities can be treated with dorsal onlay grafts, in major saddle nose deformities, reconstruction of the saddled nasal dorsum and tip support with two articulated pieces of rib cartilages are usually required [21]. The saddle nose deformity can also be treated with an L-shaped composite strut graft of columellar strut and two spreader grafts. The caudal end of the strut is placed between the medial crura and secured to the anterior nasal spine, while the superior ends of the spreader grafts are attached on both sides to the existing dorsal septal parts.

These spreader grafts provide support to the nasal wall, prevent collapse of the nasal vault, and address the problem of cartilage warping [22]. Using this technique, reconstruction of the nasal dorsum and anterior parts of the septum can be performed after tumor resection of the nasal cavity with removal of the septum (Fig. 3).

Surgical technique for positioning of spreader grafts

Either endonasal or external rhinoplasty approaches can be used for positioning of spreader grafts (Figs. 1, 2). The choice of the approach depends on the individual surgeon’s

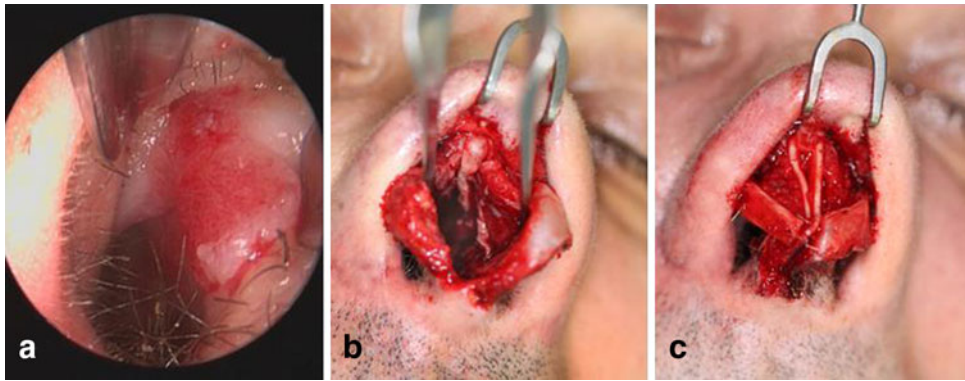


Fig. 3 Reconstruction of the nasal dorsum with spreader grafts. **a** Squamous cell carcinoma of the nasal septum on the right side, **b** Remaining defect of the anterior nasal septum after complete resection of the septal tumor with free margins, **c** Reconstruction of the nasal dorsum with spreader grafts connecting to the remnants of the

septal cartilage and to the columellar strut. *Lower lateral* cartilage on the *right side* was built with a cartilage graft. The *upper* and *lower lateral* cartilages were attached to these grafts to reconstitute the middle vault and nasal tip

preference. The procedure is usually performed under general anesthesia. The nasal skin and the underlying soft tissues are elevated in order to distinctly expose the lower and upper lateral cartilages, upper part of septal cartilage and nasal bones. Typically, the upper lateral cartilages are separated from the septal cartilage and the excess nasal bones are removed in order to open the nasal roof.

The spreader grafts are usually harvested from septal cartilage and shaped in rectangular bars, approximately 2–3 cm long, 3–5 mm wide, and 1.5 mm thick. Auricular cartilage from cavum concha can also be used for the spreader graft [23] especially in revision rhinoplasty with inadequate septal cartilage or the surgeon's preference. Next, the harvested cartilages are positioned between the upper lateral cartilage and the upper part of septal cartilage on both sides. The graft may be placed only on one side if indicated. However, it is critical that the spreader graft extends to cover the k-area especially, under the nasal bones. Finally, the cartilages are fixed together with 5–0 polydioxanone sutures (Figs. 1, 2).

Materials for spreader grafts

Spreader grafts are usually linear strips of autologous cartilages, which may be harvested from the septal cartilage, aural (conchal) cartilage, or rib cartilage [24]. Other materials which have been used as spreader grafts are hyaluronic acid (Restylane[®]) [25], calcium hydroxylapatite (Radiesse[®]) [26], high-density porous polyethylene (Medpor[®]) [27, 28], and polymer of polylactic and polyglycolic acid (Lactosorb[®]) [29]. The technique of injection of calcium hydroxyapatite and hyaluronic acid was described by Nyte [25, 26] and the procedure was used to increase the internal nasal valve angle and maintenance of nasal inspiration. Although the autolo-

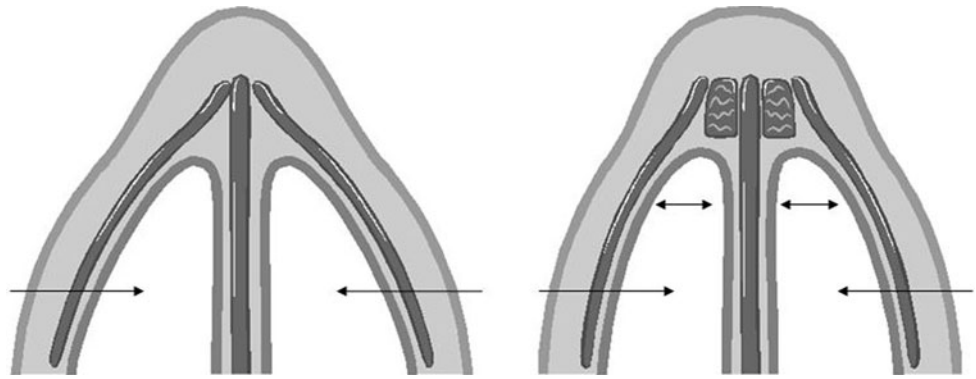
gous spreader graft is readily available in most primary cases, finding a long segment of cartilage to maintain the appropriate relationship between the septum and the upper lateral cartilage especially in revision surgery is not always easy. The synthetic materials can be useful in revision surgeries, especially where there is inadequate cartilage [27, 29].

Limitations of spreader grafts and alternatives

Spreader grafts play a useful role in the treatment of nasal valve collapse by widening the nasal valve angle with variable degrees of success [2, 5, 7, 11, 30, 31]. The values of spreader grafts have been reported to include improvement in nasal valve function and aesthetic outcome [10, 30, 31]. The improvement in nasal patency has been attributed to the widening effect in the valve area, as well as the increased resistance against inspiratory pressure caused by the grafts, which avoids nasal valve collapse [30]. The extent of lateralization of the upper lateral cartilage from the septum by the spreader graft is usually influenced by the graft thickness and the visible wideness of the nose. The spreader graft is limited in its ability to adequately support and lateralize the lateral nasal wall hence reducing its functional outcome [8, 11, 30, 31]. To clarify this limitation, Fig. 4 shows the insufficiency of the lateral nasal wall during inspiration after insertion of spreader grafts.

As mentioned before, there are some alternatives to classical spreader grafts proposed in the literature for treatment of nasal valve collapse. Alar batten grafts are especially useful for addressing nasal valve collapse caused by a weak lateral nasal wall [8]. The insertion of alar batten grafts into a precise pocket via a limited endonasal or external rhinoplasty approach to the site of maximal lateral nasal wall collapse had been demonstrated to allow for the adequate

Fig. 4 Schematic presentation of nasal valve collapse due to medialization of the caudal margin of the upper lateral cartilage related to insufficiency of the lateral nasal wall during inspiration. Spreader grafts act to widen the middle nasal vault without any effect on nasal valve collapse. **a** Before surgery, **b** After positioning of spreader grafts



lateralization of this part [8, 32]. Typically, curved septal or auricular cartilage is used. The positioning of the graft depends on whether internal or external nasal valve collapse is to be treated. The convex surface of the cartilage must be oriented laterally to allow for maximal lateralization of the collapsed portion of the lateral nasal wall. This alar batten graft will bring about lateralization of the lateral nasal wall and also resist the negative inspiratory forces that collapse the lateral nasal wall. A novel method for internal nasal valve reconstruction with H-graft has been recently described with the benefit of an improved stability of the graft on septal dorsum as well as having the combined advantages of spreader and splay effect [33]. This technique addresses the limitations of spreader grafts by providing lateralization of lateral nasal wall.

Another limitation of spreader grafts is the need for long enough cartilage grafts usually harvested from the septal cartilage. Especially, in cases of secondary rhinoplasty or after septoplasty, it is difficult to obtain adequately long and straight cartilage grafts from the septum. An alternative technique to use the upper lateral cartilage for spreader grafts has been described [29, 34–36]. This auto-spreader flap is a technique in which the mucoperichondrium of the underside of the upper lateral cartilage is elevated and then released from its cartilaginous and bony attachments in a vertical fashion. The upper lateral cartilage is thereafter rolled on itself to form a spreader flap while reducing the profile of the dorsum. This technique avoids harvesting and carving cartilage for grafting from other locations [29, 36]. This technique is limited in cases of deviated dorsal septum and asymmetric dorsal aesthetic lines.

The technique of a double-layered, stepped spreader graft for the deviated nose has also been described whenever the height of the lateral wall is shorter than preferred after straightening of a deviated nose [37]. The technique requires a composite graft (doubled-layered spreader graft), which has smaller and larger cartilaginous graft parts. The composite graft was constructed by fixing a smaller cartilage graft to the side of the dorsal border of a slightly larger than normal standard spreader graft. The doubled-layered graft was used on the shorter sidewall of the nose to

reconstruct symmetrical lateral nasal walls. The smaller graft component added height to the shorter lateral nasal wall, while the larger graft functions as a usual spreader graft.

Endonasal subperichondrial placement of spreader grafts for internal nasal valve insufficiency treatment without separating the septum from the upper lateral cartilages has been reported in the literature [11]. Leaving the connection intact was explained to have the advantage of not disrupting the integrity of the middle third of the nose and preserving the smoothness of the nasal dorsum. The technique is less invasive and can be used in conjunction with other procedures aimed at improving nasal patency.

Conclusion

The value of spreader grafts in rhinoplasty cannot be underestimated. They play a valuable role in the preservation and restoration of the normal internal nasal valve angle, as well as restoration of dorsal aesthetic lines of the nasal dorsum. In addition, they provide support, maintain the straightened position of the corrected deviated cartilaginous septal dorsum and can be used for reconstruction of the saddled nasal dorsum. Their function is, however, limited in widening effect on the collapsed lateral nasal wall, which also compromises nasal patency. Alternative methods are available to circumvent these limitations.

Conflict of interest The authors declare that they have no conflict of interest.

Open Access This article is distributed under the terms of the Creative Commons Attribution Noncommercial License which permits any noncommercial use, distribution, and reproduction in any medium, provided the original author(s) and source are credited.

References

1. Toriumi DM (1995) Management of the middle nasal vault in rhinoplasty. *Operat Tech Plast Reconstr Surg* 2:16–30
2. Sheen JH (1984) Spreader graft: a method of reconstructing the roof of the middle nasal vault following rhinoplasty. *Plast Reconstr Surg* 73:230–239

3. Marakami C (2004) Nasal valve collapse. *Ear Nose Throat J* 83:163–164
4. McCaffrey TV (1990) Rhinomanometry and diagnosis of nasal obstruction. *Facial Plast Surg* 7:266–273
5. Haight JS, Cole P (1983) The site and function of the nasal valve. *Laryngoscope* 93:49–55
6. Rohrich RJ, Hollier LH (1996) Rhinoplasty with advancing age: characteristics and management. *Clin Plast Surg* 23:281–296
7. Wittkopf M, Wittkopf J, Ries WR (2008) The diagnosis and treatment of nasal valve collapse. *Curr Opin Otolaryngol Head Neck Surg* 16:10–13
8. Becker DG, Becker SS (2003) Treatment of nasal obstruction from nasal valve collapse with alar batten grafts. *J Long Term Eff Med Implants* 13:259–269
9. Constantinides M, Doud Galli SK, Miller PJ (2002) A simple and reliable method of patients evaluation in the surgical treatment of nasal obstruction. *Ear Nose Throat J* 81:734–737
10. Kobayashi R, Miyazaki S, Karaki M, Kobayashi E, Karaki R, Akiyama K, Matsubara A, Mori N (2011) Measurement of nasal resistance by rhinomanometry in 892 Japanese elementary school children. *Auris Nasus Larynx* 38:73–76
11. Andre RF, Paun SH, Vuyk HD (2004) Endonasal spreader graft placement as treatment for internal nasal valve insufficiency: no need to divide the upper lateral cartilage from the septum. *Arch Facial Plast Surg* 6:240–243
12. Park SS (1998) The flaring suture to augment the repair of the dysfunctional nasal valve. *Plast Reconstr Surg* 101:1120–1122
13. Kamer FM, Churukian MM (1984) Shield graft for the nasal tip. *Arch Otolaryngol* 110:608–610
14. Rhee JS, Arganbright JM, McMullin BT, Hannley M (2008) Evidence supporting functional rhinoplasty or nasal valve repair: a 25 year systematic review. *Otolaryngol Head Neck Surg* 139:10–20
15. Jin HR, Won TB (2007) Nasal hump removal in Asians. *Acta Otolaryngol Suppl* 558:95–101
16. Ramirez OM, Pozner NJ (1996) Treatment by separation of its components and internal cartilage splinting. *Clin Plast Surg* 23:327–332
17. Patterson CN (1981) Surgery of the crooked nose. *Laryngoscope* 91:939–942
18. Mendelsohn M (2005) Straightening the crooked middle third of the nose: using porous polyethylene extended spreader grafts. *Arch Facial Plast Surg* 7:74–80
19. Daniel RK, Brenner KA (2006) Saddle nose deformity: a new classification and treatment. *Facial Plast Surg Clin N Am* 14:301–312
20. Vuyk HD, Watts SJ, Vindayak B (2000) Revision rhinoplasty: review of deformities, etiology and treatment strategies. *Clin Otol* 25:476–481
21. Bilen BT, Kilinc H (2007) Reconstruction of saddle nose deformity with 3-dimensional costal cartilage graft. *J Cran Surg* 18:511–515
22. Daniel RK (2007) Rhinoplasty: septal saddle nose deformity and composite reconstruction. *Plast Reconstr Surg* 119:1029–1043
23. Murrell GL (2004) Auricular cartilage grafts and nasal surgery. *Laryngoscope* 114:2092–2102
24. Deylamipour M, Azarhoshangh A, Karimi H (2005) Reconstruction of the internal nasal valve with a splay conchal graft. *Plast Reconstr Surg* 116:712–720
25. Nyte CP (2007) Hyaluronic acid spreader-graft injection for internal nasal valve collapse. *Ear Nose Throat J* 86:272–273
26. Nyte CP (2006) Spreader graft injection with calcium hydroxylapatite: a nonsurgical technique for internal nasal valve collapse. *Laryngoscope* 116:1291–1292
27. Gürlek A, Celik M, Fariz A, Ersöz-Oztürk A, Eren AT, Tenekeci G (2006) The use of high-density porous polyethylene as a custom-made nasal spreader graft. *Aesthetic Plast Surg* 30:34–41
28. Reiffel AJ, Cross KJ, Spinelli HM (2011) Nasal spreader grafts: a comparison of medpor to autologous tissue reconstruction. *Ann Plast Surg* 66:24–28
29. Gruber RP, Park E, Newman J, Berkowitz L, Oneal R (2007) The spreader flap in primary rhinoplasty. *Plast Reconstr Surg* 119:1903–1910
30. Ingels KJ, Orhan KS, van Heerbeek N (2008) The effect of spreader grafts on nasal dorsal width in patients with nasal valve insufficiency. *Arch Facial Plast Surg* 10:354–356
31. Faris C, Koury E, Kothari P, Frosh A (2006) Functional rhinoplasty with batten and spreader grafts for correction of internal nasal valve incompetence. *Rhinology* 44:114–117
32. Toriumi DM, Josen J, Weinberger M, Tardy ME Jr (1997) Use of alar batten grafts for correction of nasal valve collapse. *Arch Otolaryngol Head Neck Surg* 123:802–808
33. Tastan E, Demirci M, Aydin E, Aydogan F, Kazikdas KC, Kurkcuoglu M, Ugur MB (2011) A novel method for internal nasal valve reconstruction: H-graft technique. *Laryngoscope* 121:480–486
34. Byrd HS, Meade RA, Gonyon DL (2007) Using the autospreader flap in primary rhinoplasty. *Plast Reconstr Surg* 119:1897–1902
35. Oneal RM, Berkowitz RL (1998) Upper lateral cartilage spreader flaps in rhinoplasty. *Aesthet Surg J* 18:370–371
36. Yoo S, Most SP (2011) Nasal airway preservation using the autospreader technique. Analysis of outcomes using a disease-specific quality of life instruments. *Arch Facial Plast Surg*. doi:10.1001/archfacial.2011.7
37. Seyhan A, Ozden S, Gungor M, Celik D (2009) A double-layered, stepped spreader graft for the deviated nose. *Ann Plast Surg* 62:604–608