

# Nasal Augmentation Using Gore-Tex

## A 10-Year Experience

Michael S. Godin, MD; S. Randolph Waldman, MD; Calvin M. Johnson, Jr, MD

**Objective:** To determine on an ongoing basis the safety and efficacy of expanded polytetrafluoroethylene (Gore-Tex soft tissue patch and preformed nasal implants) as an implant in rhinoplasty.

**Design:** A retrospective study of 309 consecutive patients who underwent rhinoplasty, including augmentation with Gore-Tex, during a 10-year period.

**Setting:** Two major academic medical centers and 2 private office surgical centers.

**Intervention:** One hundred sixty-two patients (52%) presented for primary rhinoplasty; the remaining 147 (48%) presented for revision surgery. All received Gore-Tex implants to augment the nasal dorsum and/or base. The grafts ranged from 1 to 10 mm in thickness. Follow-up ranged from 5 months to 10 years, 5 months, with an average of 40.4 months.

**Main Outcome Measures:** Clinically noted compli-

cations and patient satisfaction.

**Results:** Ten (3.2%) of 309 grafts became infected and were removed. One graft was removed and 1 graft was modified and replaced postoperatively because of excessive augmentation. Infection requiring removal occurred in 8 patients (5.4%) undergoing revision rhinoplasty and in 2 patients (1.2%) undergoing primary rhinoplasty. Nasal septal perforation was present preoperatively in 3 of the patients who developed infection requiring removal, and we consider it a contraindication for nasal Gore-Tex implantation.

**Conclusions:** Gore-Tex remains an effective implant material for nasal augmentation in rhinoplasty. The complication rate in primary cases is low. The risk of infection necessitating removal rises significantly in revision cases, where its use may still be desirable but must be weighed more carefully.

*Arch Facial Plast Surg. 1999;1:118-121*

**E**XPANDED polytetrafluoroethylene (Gore-Tex; W. L. Gore and Associates, Flagstaff, Ariz) has found wide acceptance in the field of facial plastic and reconstructive surgery. While the range of uses for this versatile material in cosmetic surgery is extensive, reporting of intermediate and long-term results in the medical literature is not. Waldman<sup>1</sup> published an early report in 1991, describing an encouraging experience with Gore-Tex implantation during rhinoplasty in 17 patients. These patients were included in the subsequent report by Godin et al<sup>2</sup> on a series of 137 patients who received Gore-Tex nasal implants made of varying thicknesses of the soft tissue patch material, with a maximum follow-up period of 6 years, 8 months.

This article is the next installment in this series. The group of patients has grown to 309 and maximum follow-up is now 10 years, 5 months. Preformed nasal implants made of Gore-Tex and fluorinated ethylene propylene-reinforced soft tissue patch materials have become available since our last report, and our experience with them is detailed in this article. During this period, we have observed the emergence of important

*For commentary  
see page 122*

trends in the occurrence of complications that are also reported here. We have gradually modified how and in whom we use these implants, and the purpose of this article is to share this experience.

*From the Department of Otolaryngology, Medical College of Virginia Campus, Virginia Commonwealth University, Richmond (Dr Godin); and the Hedgewood Surgical Center, New Orleans, La (Dr Johnson). Dr Waldman is in private practice in Lexington, Ky.*

## PATIENTS AND METHODS

Three hundred nine patients underwent rhinoplasty with Gore-Tex implantation from June 1987 to August 1997. One hundred sixty-two (52%) of the operations were primary cases and 147 (48%) were revisions.

The surgical procedures were performed by 3 different facial plastic surgeons (M.S.G., S.R.W., and C.M.J.) in both major teaching hospitals and private office operating room settings. Resident physicians were never the primary surgeon in any of these procedures. Follow-up ranged from 5 months to 10 years, 5 months, with an average of 40.4 months.

Gore-Tex subcutaneous augmentation material (SAM) sheets in thicknesses of 1, 2, and 4 mm, reinforced SAM implants in thicknesses of 4.5 and 7.0 mm, and preformed reinforced nasal implants, 1 of 2.2-mm and 1 of 3.4-mm thickness, were fashioned to appropriate shapes and placed. The overwhelming majority of grafts were used to augment the nasal dorsum, although augmentation of the premaxilla was also performed in several cases.

## RESULTS

No displacement or resorption of any of the grafts was noted. One implant was removed 5 months postoperatively because of excessive augmentation. The implant was easily removed through an intercartilaginous incision, which was done under local anesthesia in the office, and no further augmentation was required. A second graft, measuring 6 mm in thickness, was judged to be excessive in size 2 weeks after primary rhinoplasty in the setting of severe maxillofacial trauma. It was removed in the operating room, reduced in size using a No. 10 blade, and replaced through an open rhinoplasty approach. In both cases, the patients healed well and were pleased with their results.

The incidence of complications relative to implant type and primary or revision surgery is summarized in the **Table**. A *complication* was defined as infection of the graft necessitating its removal. The overall complication rate was 3.2% (10 of 309 cases). The difference in occurrence of complications between the group of patients undergoing primary rhinoplasty (1.2%) and revision rhinoplasty (5.4%) was significant ( $P < .02$ ).

The 299 patients (96.8%) with Gore-Tex implants that did not become infected were pleased with their results (**Figure 1** and **Figure 2**). None of these patients had any complaints related to the position or feel of the synthetic implants on postoperative office visits.

## COMMENT

The value of long-term follow-up of the safety and efficacy of surgical procedures is undeniable. This is particularly true concerning implant materials. The surgical literature is replete with examples of synthetic implants

**Incidence of Complications Relative to Implant Type\***

Implant Type	Primary Cases		Revision Cases		Total Cases
	No.	Complication	No.	Complication	
1-, 2-, 4-mm SAM	157	2	132	7	<b>289</b>
4.5-mm SAM reinforced	2	0	9	0	<b>11</b>
7.0-mm SAM reinforced	2	0	5	1	<b>7</b>
2.2-mm Preformed	0	0	1	0	<b>1</b>
3.4-mm Preformed	1	0	0	0	<b>1</b>
<b>Total, No. (%)</b>	<b>162</b>	<b>2 (1.2)</b>	<b>147</b>	<b>8 (5.4)</b>	<b>309</b>

\*SAM indicates subcutaneous augmentation material.

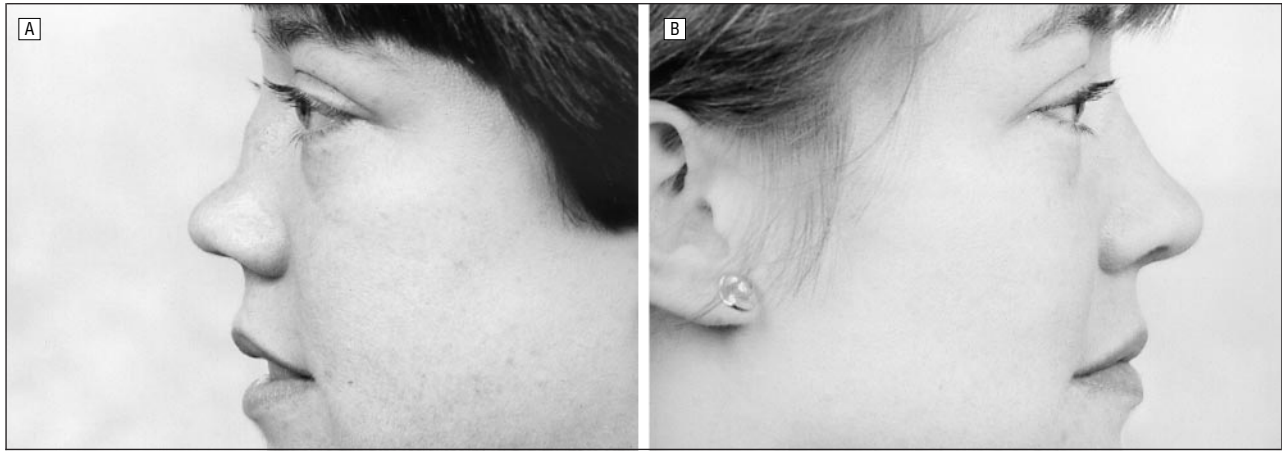that have been met with initial enthusiasm and gained widespread use, only to prove unreliable or disadvantageous and eventually fall out of favor with the surgical community.<sup>3</sup>

Gore-Tex, however, enjoys a long history of use in other surgical specialties, such as vascular surgery,<sup>4</sup> and millions of grafts have been placed for more than 20 years with remarkably good biocompatibility. The combination of a minimal inflammatory response with a tendency toward gradual increase in stability of the material in the body over time, as demonstrated by Maas et al<sup>5</sup> in an animal model, translates to excellent implant characteristics. One important caution raised by Schoenrock and Repucci<sup>6</sup> in their report of 750 implants is the importance of avoiding direct contact between the graft and the dermis, as this approximation may lead to an increase in inflammation and graft rejection.

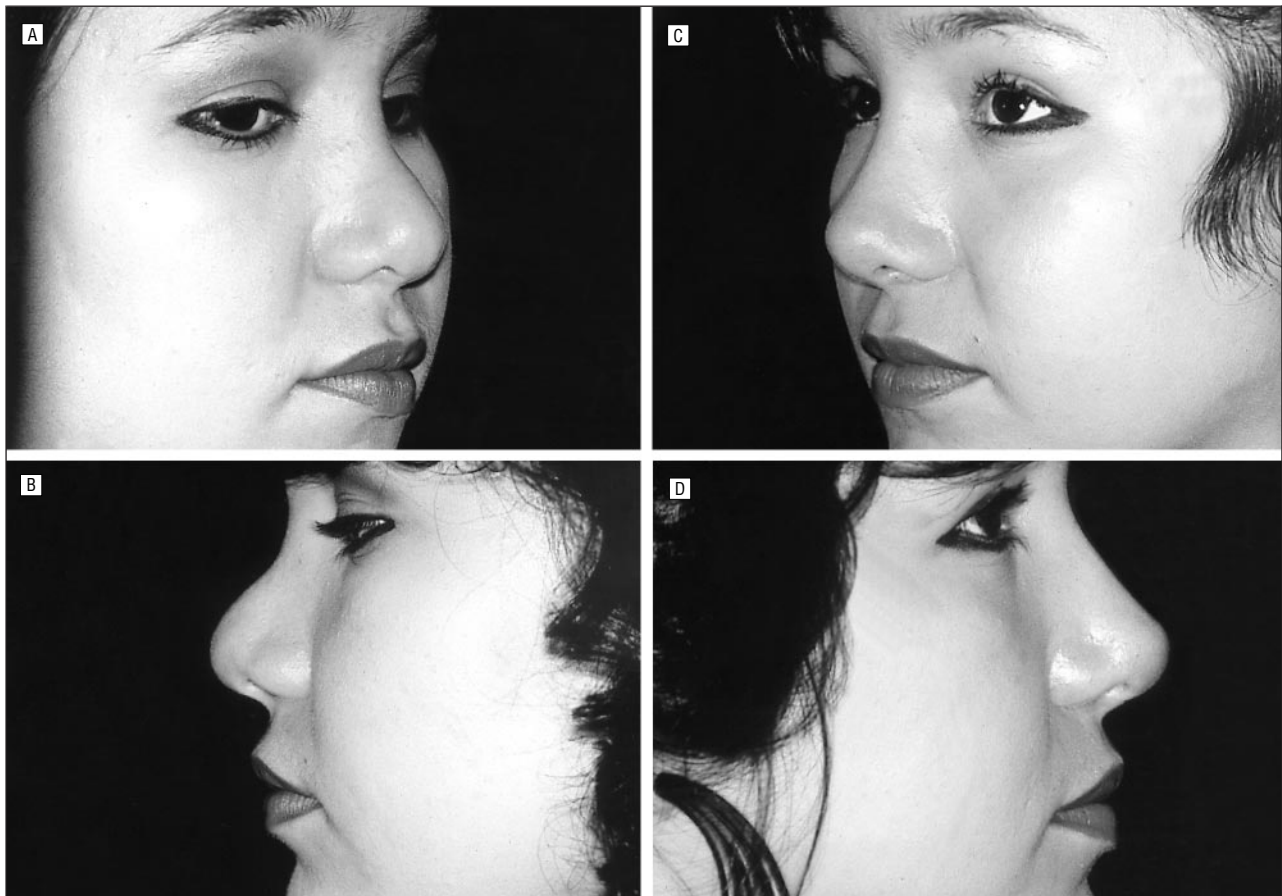
Certainly there is increased opportunity for graft contact with the dermis in revision rhinoplasty. The normally thin subcutaneous tissues of the nasal skin may be further attenuated by rhinoplasty. Scar tissue formation and changes in lymphatic drainage may further predispose to problems. Therefore, common sense would dictate that any graft, especially a synthetic one, must be used with care in revision rhinoplasty.

The incidence of complications in patients undergoing primary rhinoplasty was 1.2%. This lower incidence of problems in primary rhinoplasty is consistent with the report of Conrad and Gillman,<sup>7</sup> who had an overall complication rate of 2.7% in 189 patients receiving Gore-Tex nasal implants, but only 1 complication (1.9%) in a primary rhinoplasty case.

With longer follow-up, we have seen our overall complication rate rise slightly (2.2%-3.2%). The increase has clearly been caused by problems in the revision rhinoplasty group. Grafts have required removal as soon as 1 month after placement and as long as 3 years, 8 months after placement. The average length of time between placement and removal in the 10 patients with complications was 16 months. The only predisposing factor that we were able to identify was the presence of a nasal septal perforation before surgery, which is exceedingly rare in our overall patient population, but was present in 3 (30%) of the 10 patients who required implant removal for infection. We now regard nasal septal perforation as a contraindication to Gore-Tex graft placement.



**Figure 1.** Preoperative (A) and postoperative (B) views of a patient who underwent primary rhinoplasty with a 10-mm Gore-Tex graft for severe saddle-nose deformity.



**Figure 2.** Preoperative (A and B) and postoperative (C and D) views of a patient who underwent revision rhinoplasty with Gore-Tex implantation.

As new forms of Gore-Tex have been produced, our surgical techniques have changed to encompass them. The availability of reinforced implants in thicknesses of 4.5 and 7.0 mm has obviated the need for suturing multiple pieces of soft tissue patch together in many cases. It is still necessary, however, to occasionally add to the thicknesses of these grafts, and monofilament nonabsorbable sutures and soft tissue patch (SAM) grafts are still used to do this. In both of the preformed implants that we placed, SAM grafts were fashioned and sutured

to the implant to provide needed additional augmentation. The principles of implant modification and stabilization, maintenance of a thick, healthy soft tissue covering, and perioperative care advanced in our last publication have not changed.<sup>2</sup>

#### CONCLUSIONS

With increased length of follow-up, the true biocompatibility of a synthetic implant material may be accu-

rately discerned. Gore-Tex has certainly stood the test of time in the field of vascular surgery<sup>4</sup> and has an excellent record, thus far, in facial reconstructive and cosmetic surgery as well. Our experience with using Gore-Tex for more than 10 years has demonstrated that it remains an effective implant material for nasal augmentation in rhinoplasty. The complication rate in primary cases, such as cosmetic improvement of the platyrrhine nose is low, and the material can be carved and placed to look and feel quite natural. The risk of infection necessitating removal rises significantly in revision cases, where the surgeon must weigh such factors as skin thickness, technical difficulty, and his or her own experience carefully before proceeding with any implant.

*Accepted for publication February 9, 1999.*

*Presented at the Seventh International Symposium, American Academy of Facial Plastic and Reconstructive Surgery, Orlando, Fla, June 19, 1998.*

*The authors thank Evelyn Maillho-Schwartz; Sally Carpenter, RN; Patricia Ezell; and Chris Sellers, CRNA,*

*for their invaluable assistance in gathering data for this article.*

*Reprints: Michael S. Godin, MD, Facial Plastic and Reconstructive Surgery, 410 Libbie Ave, Richmond, VA 23226 (e-mail:msgmd@richmond.infi.net).*

## REFERENCES

1. Waldman SR. Gore-Tex for augmentation of the nasal dorsum: a preliminary report. *Ann Plast Surg.* 1991;26:520-525.
2. Godin MS, Waldman SR, Johnson CM Jr. The use of expanded polytetrafluoroethylene (Gore-Tex) in rhinoplasty: a 6-year experience. *Arch Otolaryngol Head Neck Surg.* 1995;121:1131-1136.
3. Warren LG. Gore-Tex facial implants. *Plast Reconstr Surg.* 1997;98:1899-1900.
4. McAuley CE, Steed DL, Webster MW. Seven-year follow-up of expanded polytetrafluoroethylene (PTFE) femoropopliteal bypass grafts. *Ann Surg.* 1984;199:57-60.
5. Maas CS, Gnepp DR, Bumpous J. Expanded polytetrafluoroethylene (Gore-Tex soft tissue patch) in facial augmentation. *Arch Otolaryngol Head Neck Surg.* 1993;119:1008-1014.
6. Schoenrock LD, Repucci AD. Correction of subcutaneous facial defects using Gore-Tex. *Facial Plast Surg Clin North Am.* 1994;2:373-387.
7. Conrad K, Gillman G. A 6-year experience with the use of expanded polytetrafluoroethylene in rhinoplasty. *Plast Reconstr Surg.* 1998;101:1675-1683.

### Quotable

You have to learn what others have done because you won't live long enough to make all the mistakes yourself.

*Frank McDowell, MD*